

SUBRETINAL DRUSENOID DEPOSITS AND SOFT DRUSEN

Are They Markers for Distinct Retinal Diseases?

ROBERT J. THOMSON, BS,* JOSHUA CHAZARO, BS,*† OSCAR OTERO-MARQUEZ, MD,‡ GERARDO LEDESMA-GIL, MD,‡§¶ YUEHONG TONG, PhD,‡*** ARIELLE C. COUGHLIN, BA,†† ZACHARY R. TEIBEL, MD,‡‡ SHARMINA ALAUDDIN, MD,‡ KATY TAI, BA,‡ HARRIET LLOYD, BA,‡ MARIA SCOLARO, MA,§ ARUN GOVINDAIAH, MS,§§ ALAUDDIN BHUIYAN, PhD,** MANDIP S. DHAMOON, MD,¶¶ AVNISH DEOBHAKTA, MD,‡ JAGAT NARULA, MD,*** RICHARD B. ROSEN, MD,‡ LAWRENCE A. YANNUZZI, MD,§ K. BAILEY FREUND, MD,§††† R. THEODORE SMITH, MD, PhD‡***

Purpose: Soft drusen and subretinal drusenoid deposits (SDDs) characterize two pathways to advanced age-related macular degeneration (AMD), with distinct genetic risks, serum risks, and associated systemic diseases.

Methods: One hundred and twenty-six subjects with AMD were classified as SDD (with or without soft drusen) or non-SDD (drusen only) by retinal imaging, with serum risks, genetic testing, and histories of cardiovascular disease (CVD) and stroke.

Results: There were 62 subjects with SDD and 64 non-SDD subjects, of whom 51 had CVD or stroke. SDD correlated significantly with lower mean serum high-density lipoprotein (61 ± 18 vs. 69 ± 22 mg/dL, $P = 0.038$, t -test), CVD and stroke (34 of 51 SDD, $P = 0.001$, chi square), *ARMS2* risk allele ($P = 0.019$, chi square), but not with *CFH* risk allele ($P = 0.66$). Non-SDD (drusen only) correlated/trended with *APOE2* ($P = 0.032$) and *CETP* ($P = 0.072$) risk alleles (chi square). Multivariate independent risks for SDD were CVD and stroke ($P = 0.008$) and *ARMS2* homozygous risk ($P = 0.038$).

Conclusion: Subjects with subretinal drusenoid deposits and non-SDD subjects have distinct systemic associations and serum and genetic risks. Subretinal drusenoid deposits are associated with CVD and stroke, *ARMS2* risk, and lower high-density lipoprotein; non-SDDs are associated with higher high-density lipoprotein, *CFH* risk, and two lipid risk genes. These and other distinct associations suggest that these lesions are markers for distinct diseases.

RETINA 42:1311–1318, 2022

Multiple risk factors have been identified for age-related macular degeneration (AMD), but pathogenic mechanisms are known only in part, a major knowledge gap. We suggest a new approach to closing that gap. Finding and studying distinct disease pathways within the whole of AMD could facilitate insight into their individual mechanisms. Specifically, we propose that there are two distinct disease pathways involving the two major lesions of intermediate AMD, soft drusen beneath the retinal pigmented epithelium (RPE) and subretinal drusenoid deposits (SDDs) above the RPE,¹ demonstrated in vivo by spectral domain optical coherence tomography (SD-OCT)² (Figure 1). These lipid-containing deposits, of different biochemical compositions,¹ can occur in the same eye (Figure 1C) and can

progress to either of the 2 recognized forms of advanced AMD, neovascularization (NV) and macular atrophy (MA),^{3,4} for which SDDs, aka reticular pseudodrusen, confer twice the risk.^{5–7}

Anatomically, SDDs, relative to drusen, are associated with choroidal thinning and topographic alignment with choroidal watershed zones, suggesting hypoxia in their pathogenesis.^{8,9} However, relationships of SDD to actual choriocapillaris (CC) insufficiency on optical coherence tomography angiography¹⁰ remain controversial because of projection artifacts. Hence, although combining CC insufficiency and SDDs as the reticular macular disease phenotype of AMD has been proposed,¹¹ we will confine this report to the SDDs themselves. Extraordinary recent progress on computational optical coherence tomography

angiography of the choriocapillaris will doubtlessly answer the SDD/CC vascular question.¹²

Systemic vascular relationships with SDDs have also been noted, especially with coronary artery disease in small case-control studies.^{3,4} Previous studies relating systemic vascular disease and AMD in general are not definitive,^{13,14} and a large meta-analysis found no associations.¹⁵ Hence, further data relating these diseases specifically to subjects with SDDs would be of high significance to both disorders. Similarly, genetic risks for AMD are established, but, with the exception of *ARMS2* risk for SDD,¹⁶ differential risks for the two deposits are unknown, and finding others would fill a significant gap in the genetics of AMD.

Established features differentiating the lesions themselves include multimodal imaging: Scanning laser ophthalmoscopy, with autofluorescence and near infrared reflectance (NIR) imaging, clearly identifies SDD as hypofluorescent on autofluorescence and hyporeflectant on NIR,¹¹ properties not shared by drusen. Anatomically, SDDs preferentially localize with rods while drusen localizes with cones.¹⁷ Additional evidence differentiates patients with SDDs (with or without drusen) and those with only drusen: Patients with SDD, strikingly, are mostly female and have decreased longevity.⁷ SDDs are specifically associated with Type 3 NV,¹⁸

nonexudative, multilobular geographic atrophy,⁶ and adverse impact on rod-mediated dark adaptation.¹⁹

It is important to realize, however, that neither associations nor outcomes are disease mechanisms. In the case of disease outcome, combined cases of SDD and drusen fare worse than either phenotype alone. The incidence of fellow eye NV was significantly higher, and the area of CC signal deficit on optical coherence tomography angiography was significantly greater in soft drusen plus SDD eyes than with either phenotype alone.^{20,21} Hence, eyes with combined lesions are not the same as those with only one. However, the simplest explanation here may be that a tissue with two diseases (or two manifestations of a single disease) fares worse than with just one, rather than arguing that the combination itself is a phenotype.

In this article, we extend these distinctions with genetics, serum risk markers, and associations with vascular disease. For this purpose, we classified patients with AMD, as has been customary in previous studies,^{16,22,23} into two groups: SDD group, with or without soft drusen, and non-SDD group (drusen only) by retinal imaging. The purpose of these groupings is to show that patients with SDDs, regardless of drusen, have different characteristics, as just elucidated, from non-SDD groups. For example, in the Comparison of AMD Treatments Trials, patients in the SDD group had higher frequency of the *ARMS2* risk allele and lower frequency of the risk allele *CFH Y402H*, compared with the non-SDD group,²³ replicating our previous findings.¹⁶ Thus, with the purpose that our results can be directly related to the literature and to these gaps in our understanding, we also direct our study and hypotheses to these two groups of patients.

Hypothesis: 1. Subjects with SDD, with or without drusen, and those without SDD (soft drusen only) have different systemic associations, serum risks, and genetic risks.

Hypothesis: 2. These lesions are markers for distinct diseases that can both result in advanced AMD.

Hypothesis 2 will be supported by new associations but cannot be proven without disease mechanisms. Thus, different end-stages attendant to these different deposits have been reviewed previously.²⁴ The open question, considered here, is whether they are manifestations of a common pathophysiology, the disease intermediate AMD,²⁴ or may represent distinct pathophysiologies, with actual disease mechanisms remaining to be elucidated.

Methods

This prospective study was conducted at two tertiary vitreoretinal referral centers in New York City: Vitreous

From the *McGovern Medical School at the University of Texas Health Science Center, Houston, Texas; †Loyola University Chicago Stritch School of Medicine, Maywood, Illinois; ‡Department of Ophthalmology, New York Eye and Ear Infirmary of Mount Sinai, New York, New York; §Vitreous Retina Macula Consultants of New York, New York, New York; ¶Retina Department, Institute of Ophthalmology Fundación Conde de Valenciana, Mexico City, Mexico; **Department of Ophthalmology, Icahn School of Medicine at Mount Sinai, New York, New York; ††Icahn School of Medicine at Mount Sinai, New York, New York; ‡‡Hackensack University Medical Center, Hackensack, New Jersey; §§iHealthscreen Inc., New York, New York; ¶¶Department of Neurology, Icahn School of Medicine at Mount Sinai, New York, New York; ***Department of Cardiology, Icahn School of Medicine at Mount Sinai, New York, New York; and †††Department of Ophthalmology, NYU Grossman School of Medicine, New York, New York.

Regeneron Pharmaceuticals Investigator-Initiated Study, Research to Prevent Blindness Challenge Grant, Macula Foundation (K.B.F.), Bayer-Global Ophthalmology Awards (G.L.G.), and International Council of Ophthalmology-Alcon Fellowship (O.O.M.).

R. B. Rosen is a consultant to OptoVue, Boehringer-Ingelheim, Astellas, Genentech-Roche, NanoRetina, OD-OS, Regeneron, Bayer, Diopsys, and Teva. He has personal financial interests in Opticology, Guardian, and CellView. K. B. Freund is a consultant to Regeneron, Allergan, Zeiss, Bayer, Heidelberg Engineering, and Novartis. He receives research funding from Genentech/Roche. R. T. Smith is a consultant to Ora Technologies and an equity holder in MacRegen, Inc. None of the other authors has any conflicting interests to disclose.

R. J. Thomson and J. Chazaro contributed equally to this work.

Reprint requests: R. Theodore Smith, MD, PhD, New York Eye and Ear Infirmary of Mount Sinai, 310 E 14th Street, New York, NY 10003; e-mail: rts1md@gmail.com

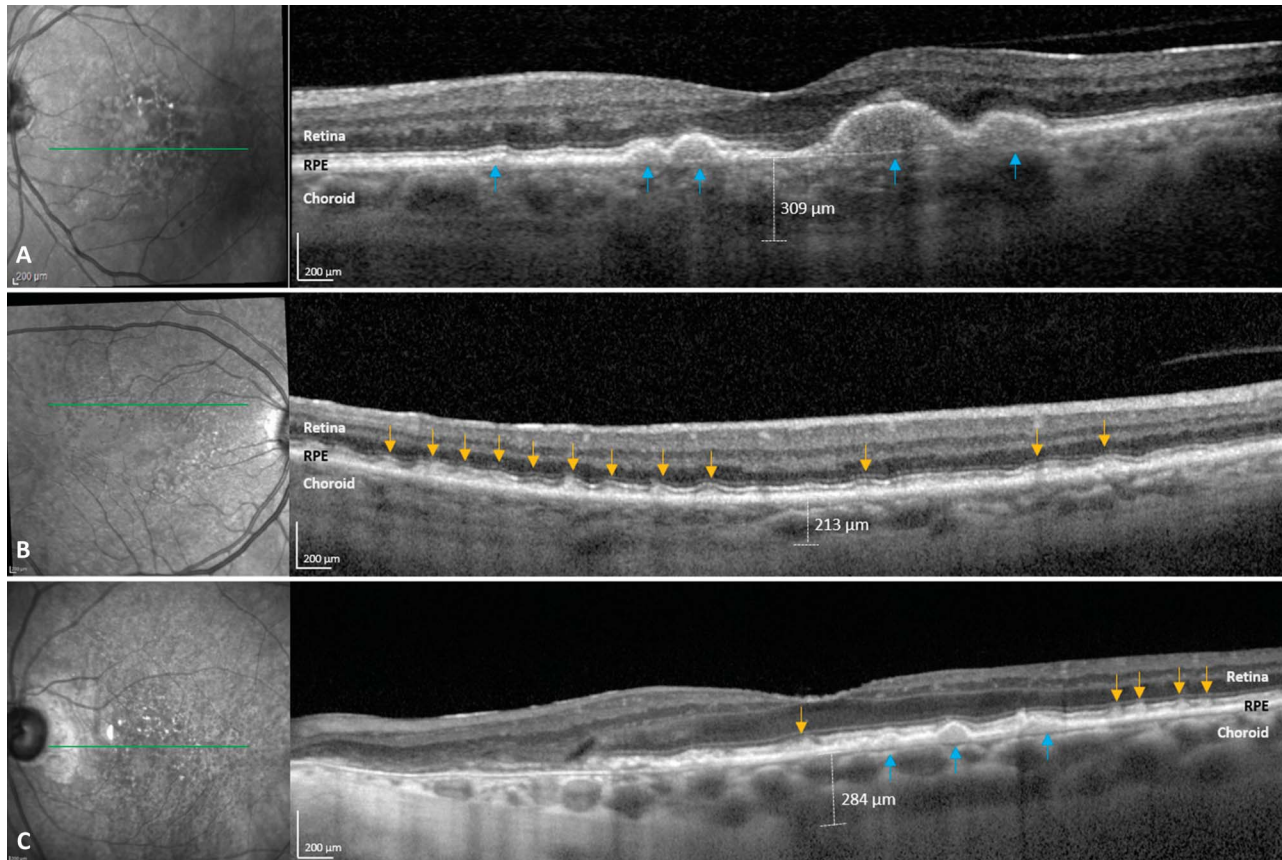


Fig. 1. Multimodal imaging of soft drusen and SDD in AMD. Left: near infrared reflectance images. Right: spectral domain optical coherence tomography images. The green lines on the NIR images denote the location of the corresponding B-scans on SD-OCT. **A.** Soft drusen. NIR: soft drusen have a hyperreflectant appearance. SD-OCT: soft drusen (blue arrows) lie between the basal lamina of the RPE and the inner collagenous layer of Bruch membrane, which is seen intermittently where the RPE is elevated. The choroidal thickness is 309 μm . **B.** Pure SDD. NIR: SDDs are fairly homogeneous and fairly uniformly spaced hyporeflectant lesions that fill compact distributions with well-defined borders, an appearance pathognomonic for SDD. Here, they are more numerous superiorly as is usually the case. SD-OCT. A few Stage I lesions not distorting the overlying EZ are seen between Stage II SDDs (yellow arrows) that are large enough to distort the EZ. In this pure SDD case (no soft drusen), the choroidal thickness is 213 μm , thinner than that in (A and C), the soft drusen and mixed phenotypes. **C.** Mixed drusen and SDD. NIR: mixed hyperreflectant soft drusen and hyporeflectant SDD. SD-OCT: soft drusen beneath the RPE (blue arrows). SDD: Stage II lesions large enough to distort the EZ (yellow arrows). The choroidal thickness is 284 μm .

Retina Macula Consultants of New York (L.Y. and K.B.F.) and Department of Ophthalmology, New York Eye and Ear Infirmary of Mount Sinai School of Medicine (MSSM) (R.B.R. and R.T.S.), from January 2019 to January 2021 with impacted recruitment secondary to the initial wave of COVID-19 during March 2020 to September 2020. The institutional review board of MSSM approved this study, which adhered to the tenets of the Declaration of Helsinki (ClinicalTrials.gov Identifier: NCT04087356).

Inclusion and Exclusion Criteria

All patients older than 50 years, diagnosed with SDD and/or large soft drusen lesions of AMD in either eye, who signed informed consent and completed a study-related questionnaire were included. Advanced AMD eyes were included, except that subjects with

bilateral NV were excluded (such eyes cannot be reliably graded for SDD). In the case of unilateral NV, with or without injections, all determinations were made on the fellow eye. Other exclusion criteria were patients with retinal degeneration other than AMD, retinal vascular diseases (e.g., diabetic retinopathy), prior retinal surgery (except intravitreal injections), inadequate quality imaging per device specifications (see imaging), and/or inconclusive medical or macular diagnoses.

Patient Evaluation

All patients' examinations included best-corrected visual acuity, intraocular pressure (mmHg), slit-lamp examination for iris color, and lens status (phakic or pseudophakic). A questionnaire covered age, age of AMD onset, antivascular endothelial growth factor

(anti-VEGF) treatment (Y/N), sex, race/ethnicity, family history of AMD, smoking history, body mass index, histories of hypertension or diabetes, use of acetylsalicylic acid, or antilipid medications. Vascular history specifically covered stroke or transient ischemic attack and the following heart disease histories: myocardial infarction, coronary artery bypass grafting, angina, arrhythmia, positive stress test, positive cardiac catheterization, stent, valve disease, and congestive heart failure of any cause. These categories of disease/criteria to include in the cardiovascular disease (CVD) and stroke groups were determined in consultation with experts in the field (J.N. and M.S.D.). All patients reporting any vascular history, after review of medical records, entered the CVD and stroke groups. The records of patients who did not report vascular histories were not reviewed.

Imaging

Volume SD-OCT scans (27 lines, automated retinal tracking, 16 scans averaged per line, quality at least [29–34], per the device specifications) and *en face* autofluorescence and NIR scans (both 30°) centered on the macula on the Heidelberg SPECTRALIS HRA + OCT (Heidelberg engineering, Heidelberg, DE) were obtained for all patients.

Image Analysis

Subretinal drusenoid deposits were identified on SD-OCT imaging as lesions of intermediate reflectivity above the RPE following a published protocol³ presence and most advanced stage were determined independently, and then to consensus by two retina specialists (G.L.G. and O.O.M.). Any differences were resolved by a senior grader (R.T.S.). Autofluorescence and NIR images were used to confirm the presence of SDD as fairly uniform, fairly uniformly spaced hypofluorescent, or hyporeflectant lesions that fill compact distributions with well-defined borders.¹¹ Dot and ribbon SDD types were not distinguished. Soft drusen were identified on SD-OCT imaging as lesions of intermediate reflectance on the Bruch membrane elevating the RPE (Figure 1). Pigment epithelial detachments were included with soft drusen. Other drusen phenotypes of lesser prevalence (calcified drusen and cuticular drusen) were not included. A large soft drusen was required to be >125 μm in diameter. Choroidal thickness in both eyes was measured on a central SD-OCT scan (Figure 1).

Serum Risk Markers for Atherosclerotic Disease

Blood samples for risk biomarkers of atherosclerotic disease²⁵ (high-density lipoprotein cholesterol [HDL-c], low-density lipoprotein cholesterol [LDL-c], triglycerides, total cholesterol, and high sensitivity C-reactive protein) were obtained and rapidly centrifuged at 1800g for 10 minutes before refrigeration. Lipid levels were measured (Quest Diagnostics, Teterboro, NJ) by spectrophotometry, and plasma levels of high sensitivity C-reactive protein were measured by using an immunoturbidimetric assay (Orion Diagnostica, Finland).

Genetic Analysis

Blood samples for DNA were immediately stored at –70°C until shipped on dry ice to LGC Genomics (LGC Biosearch Technologies, Hoddesdon, United Kingdom). Genomic DNA was extracted from peripheral blood leukocytes according to the established protocols. Genotyping was performed using a KASP (Kompetitive Allele-Specific PCR, LGC Genomics) genotyping assays designed to each target variant within 1,536-well PCR plates. Fluorescence was detected using the BMG PHERAstar (BMG Labtech GmbH, Ortenberg, DE) and genotyping calls assigned based on cluster plots within the LGC Genomics Kraken software.

The samples were assessed for single-nucleotide polymorphisms in 9 genes associated with AMD: *CFH* (Y402H allele), *ARMS2-HTRA1* (69S allele), *C3*, *C2/BF* (*BF* rs4151667, which identifies the H10 haplotype of *C2/BF*), cholesteryl ester transfer protein (*CETP*), hepatic lipase (*LIPC*), tissue inhibitor of metalloproteinase 3 (*TIMP3*), and apolipoprotein genes (*APOE2* and *APOE4*). All are risk alleles except for the protective *C2/BF*, *LIPC*, and *APOE4* alleles.²⁶

Statistical Analysis

Data scientists (A.B. and A.G.) used “IBM SPSS Statistics, version 27”; “Waikato Environment for Knowledge Analysis (WEKA), version 3.8.5,” a data modeling tool; and Microsoft Excel 365. Univariate statistics were the chi-square test for categorical variables and a two-tailed *t*-test for continuous variables, with medians, ranges, and/or interquartile ranges for nonnormally distributed data. However, *t*-tests are considered reliable even if the data are not normally distributed, if the sample size is >30, and the population from which the sample is drawn is normally distributed. *T*-tests were used only for HDL level and choroidal thickness, and sample sizes were ≥ 62. Multivariate regression determined each variable’s

significance after controlling for all other covariates. For all tests, $P < 0.05$ was considered significant.

Results

Demographics and Clinical Characteristics

Subretinal drusenoid deposits were present in 62 subjects (29 pure, without large soft drusen, and 33 mixed cases) and absent in 64 subjects (non-SDD group, pure soft drusen). Five disagreements were resolved by consensus without arbitration. For the SDD (non-SDD) groups, 67.7% (64.1%) were female and 32.3% (35.9%, NS) were male. Regarding demographic, ocular, and clinical characteristics of patients, acetylsalicylic acid use was significantly associated with SDD (53 of 62 SDD vs. 30 of 64 non-SDD, $P = 0.007$), and the mean choroidal thickness was less in SDD left eyes than in non-SDD left eyes (mean 146 ± 58 vs. $177 \pm 59 \mu\text{m}$, $P = 0.003$; median 161.5, range 78–228 μm vs. median 177.5, range 90–286 μm), and similarly for right eyes (Table 1). All other comparisons were not significant.

Serum Risk Markers for Cardiovascular Disease and Stroke

Regarding the cholesterol panel and high sensitivity C-reactive protein, the mean HDL was significantly lower in SDD (mean 61 ± 18 ; median 57, interquartile ranges 19) than in non-SDD subjects (mean 69 ± 22 , $P = 0.038$; median 69, interquartile ranges 29) as given in Table 2. All other comparisons were not significant.

Cardiovascular Disease and Stroke

Of the 126 subjects, 51 had CVD or stroke: 34 of 51 had SDD and 17 of 51 had non-SDD. Seventy-five had non-CVD or stroke, of whom 28 had SDD and 47 had non-SDD (odds ratio 3.36, 95% confidence interval 1.59–7.09, $P = 0.0012$).

Genetics

The *ARMS2* risk allele frequency was significantly higher (41.6%) in the SDD group than in the non-SDD group (28.5%; odds ratio 1.79, 95% confidence interval 1.15–3.03, $P = 0.03$). The *CFH* risk allele frequencies were similar in the 2 groups (56% and 53.2%; $P = 0.66$).

APOE2 and *CETP* risk allele frequencies were higher in the non-SDD group than in the SDD group (14.3% vs. 5.9%, and 43.6% vs. 32.5%, $P = 0.03$ and 0.07, respectively). Allele frequencies and significance of correlations with SDD or non-SDD of haplotype-tagging single-nucleotide polymorphisms from the AMD-associated loci are summarized in Table 3.

Dividing the subjects into pure SDD ($n = 29$) and pure drusen ($n = 64$), the *CFH* risk allele frequency was significantly higher (61.4%) in the pure drusen group than in the pure SDD group (36.8%; $P = 0.04$, odds ratio 2.185, 95% confidence interval 1.03–4.65). All other findings with this subdivision were NS.

Multivariate Regression

Multivariate regression found CVD or stroke and *ARMS2* homozygous risk significant for SDD risk ($P = 0.008$ and $P = 0.038$, respectively), after controlling for

Table 1. Baseline Demographic, Ocular, and Clinical Characteristics of Age-Related Macular Degeneration Patients With or Without Subretinal Drusenoid Deposits

	SDD	Non-SDD	<i>P</i>
Subjects, N	62	64	N/A
Sex (F/M), N	42/20	41/23	0.66*
Age, years, mean \pm SD	81.3 \pm 6.82	79.5 \pm 7.9	0.17†
Race (White, %)	90	84	0.31*
Previous cataract surgery, %	56	50	0.46*
Smoking history (>6 months), %	61	56	0.56*
Hypertension, %	53	55	0.86*
Diabetes, %	9	12	0.61*
Relatives with AMD, %	29	33	0.64*
Antilipid medication, %	56	42	0.10*
Aspirin/blood thinner, %	53	30	0.007*
Subfoveal ChT OD	148 \pm 53	179 \pm 54	0.001†
Subfoveal ChT OS	146 \pm 58	177 \pm 59	0.003†

Boldface values indicate significant differences.

†Independent *t*-test.

*Chi-square test.

ChT, choroidal thickness; F, female; M, male; OD, right eye; OS, left eye.

Table 2. Cholesterol Panel and C-Reactive Protein Values of Age-Related Macular Degeneration Patients With or Without Subretinal Drusenoid Deposits

	SDD	Non-SDD	P
Total cholesterol, mg/dL	182 ± 44	193 ± 37	0.13*
Triglycerides, mg/dL	121 ± 57	128 ± 73	0.55*
HDL cholesterol, mg/dL	61 ± 18	69 ± 22	0.038*
VLDL cholesterol, mg/dL	26 ± 19	27 ± 18	0.87*
LDL cholesterol calc, mg/dL	97 ± 36	97 ± 32	0.99*
hsC-reactive protein cardiac, mg/L	4.2 ± 8	3.8 ± 8	0.79*

The results are presented as mean ± SD.

Boldface values indicate significant differences.

*Independent *t*-test.

Calc, calculated; HDL, high-density lipoprotein; LDL, low-density lipoprotein; SDD, subretinal drusenoid deposits; VLDL, very-low-density lipoprotein.

all other covariates (Tables 1–3). Acetylsalicylic acid use was not analyzed for multivariate SDD risk, considering the evident strong association of vascular diseases with SDD.

Discussion

The central hypothesis presented in this article is that SDD and soft drusen are markers for two separate, but often coexisting, diseases that may result in either form of advanced AMD. The phenomenon of separate, perhaps coexisting, diseases resulting in similar poor outcomes and organ dysfunction is the norm in medicine rather than the exception, for example, the many unique paths to heart failure. What we have shown, specifically, is that patients with SDD, with or without drusen, differ significantly from non-SDD eyes in AMD in their associations with CVD and stroke, serum risks, and genetic risks, consistent with

the concept of distinct disease pathways, but not proof. As mentioned before, differences between these patients, eyes, and the lesions themselves have already accumulated from diverse disciplines: anatomy, histology, imaging, retinal function, clinical outcomes, biochemistry, and choroidal vascular anatomy.

In addition, we have shown by multivariate regression that the known *ARMS2* risk for SDD is independent of the CVD and stroke risk for SDD found herein, suggesting two independent mechanisms for SDDs themselves: molecular genetic as just discovered in the former²⁷ and vascular-related as we have demonstrated in the latter. The strong association shown here between CVD and stroke, the leading causes of death in the developed world, and SDDs, a major form of AMD, the leading cause of blindness, is particularly important. Previous studies of AMD as a whole have not found consistent relations. Specific studies of SDD in this context might lead the way to a vascular mechanism.

Table 3. Allele Frequencies of Significant Single-Nucleotide Polymorphisms From the Age-Related Macular Degeneration–Associated Loci

SNP	SDD		Non-SDD		OR (SDD/non-SDD)	95% CI	P
	N	%	N	%			
APOE2, rs7412	7	5.9	18	14.3	0.38	0.152–0.942	0.03*
C3, rs2230199	89	74.1	90	71.4	1.15	0.654–2.016	0.62*
ARMS2, rs10490924	50	41.6	36	28.5	1.79	1.151–3.034	0.03*
CFH, rs1061170	65	56	65	53.2	1.12	0.671–1.863	0.66*
LIPC, rs10468017	22	18.3	26	20.6	0.86	0.459–1.625	0.64
CETP, rs3764261	39	32.5	55	43.6	0.62	0.370–1.045	0.07*
C2/B, rs4151667	2	1.7	3	2.4	0.70	0.114–4.238	0.69
TIMP3, rs9621532	7	5.8	10	8.2	0.69	0.255–1.887	0.47*
APOE4, rs429358	9	7.5	8	6.3	1.20	0.446–3.209	0.72

Boldface values indicate significant differences.

All are AMD risk alleles except protective alleles *C2/B, *LIPC, and *APOE4.

*Chi-square test.

APOE2, apolipoprotein E2 gene; APOE4, apolipoprotein E4 gene; ARMS2, age-related maculopathy susceptibility gene; CETP, cholesteryl ester transfer protein gene; CFH, complement factor H gene; CI, confidence interval; C2/B, complement 2 fraction B gene; C3, complement C3 gene; htSNP, haplotype-tagging single-nucleotide polymorphism; LIPC, hepatic lipase gene; OR, odds ratio; SDD, subretinal drusenoid deposits; TIMP3, metalloproteinase inhibitor 3 gene.

The lipid dynamics of drusen with esterified cholesterol and SDD with nonesterified cholesterol¹ are complex. Lipid in drusen and in the plaques of atherosclerotic disease led to a long search for common mechanisms in these lesions. However, although Bruch membrane lipids do resemble plasma LDL (the major source of plaque cholesterol), the RPE itself, not plasma, is the source of both drusen and SDD per the best evidence to date: a 2-lesion, 2-compartment biogenesis model, dissimilar to atherosclerosis.¹⁷

The risk marker of low serum HDL for atherosclerotic disease, and for SDD in this study, actually runs contrary for AMD in general, with higher HDL increasing risk.²⁸ The explanation is that previous studies used color photography, which is sensitive to drusen but not SDD. They therefore indeed could show that high HDL is a risk for drusen, but with no information on SDD.²⁸ This now makes sense that low HDL, which is a risk for CVD and stroke, which we just have found are a risk for SDD, is a risk for SDD themselves and the other AMD pathway. The effect HDL has on AMD is not uniform, depending on the pathway. Furthermore, as shown in this study, eyes with only drusen have higher rates of the AMD risk alleles, *APOE2* and *CETP*, than eyes with SDD, with or without drusen. This likewise suggests that the AMD risk of these alleles, such as high HDL, is mediated through drusen.

Many (29 of 62) cases of pure SDD (without drusen) further suggest that SDD is a distinct retinal pathology. Damage from SDD then can lead, along with that of soft drusen, to advanced AMD. However, the lesions of geographic atrophy consequent to drusen or SDD still have distinguishing morphologic⁶ and autofluorescence characteristics,²⁹ consistent with different mechanisms.

This study has several limitations. The small sample size requires replication in larger cohorts. Furthermore, this study cohort is a mostly Caucasian elderly population with AMD, which requires examination in more diverse cohorts, for example, in Asians, with polypoidal choroidal vasculopathy. The SDD ribbon and dot types were not considered nor were other drusen phenotypes (calcified drusen and cuticular drusen). Vascular histories were patient reported. Detailed data on cardiac and carotid status in future studies would help interpret these results.

Strengths of this prospective study at two tertiary retina referral centers include rigorous patient selection and AMD phenotyping with high-quality multimodal imaging for drusen and SDD. Inclusion of new data from the fields of cardiovascular disease and stroke, serum risk factors, and genetics have herein been added to the already broad platform of existing evidence differentiating patients with SDD from patients with only drusen.

Conclusion

The SDD and soft drusen pathways, now considered to be components of one disease, intermediate AMD, actually may be two separate, often coexisting diseases that both can lead to advanced AMD. We have added new data to the library of differing associations and dissimilar physical attributes from systemic vascular associations, serum risks, and genetic risks. These are not proof of different cause and effect, but the growing mass of such differences, without a single significant unifying observation to balance it, is striking. Even the final stages (NV and MA) of advanced AMD are dissimilar.

There may be very real practical benefit from considering this model. As shown here, many patients with AMD demonstrate only one of these index lesions. Patient care could be personalized by consideration of the risk factors operative in given individuals. Research on the mechanisms of AMD could be guided by studying those risks that apply specifically to only one or the other pathway, for example, the independent CVD and stroke risk and *ARMS2* molecular risk for SDD; the specific HDL and *APOE2* risks for soft drusen. These distinctions could enable focused attention on specific risks and single pathways, with correspondingly higher chances of success. The specific association of cardiovascular disease and stroke with SDD in particular merits further study.

Key words: age-related macular degeneration, choroid, cardiovascular disease, drusen, genetics, risk factors, stroke, subretinal drusenoid deposits.

Acknowledgments

The authors gratefully acknowledge helpful conversations with Christine Curcio.

References

1. Oak AS, Messinger JD, Curcio CA. Subretinal drusenoid deposits: further characterization by lipid histochemistry. *Retina* 2014;34:825–826.
2. Zweifel SA, Spaide RF, Curcio CA, et al. Reticular pseudo-drusen are subretinal drusenoid deposits. *Ophthalmology* 2010; 117:303–312.e1.
3. Cymerman RM, Skolnick AH, Cole WJ, et al. Coronary artery disease and reticular macular disease, a subphenotype of early age-related macular degeneration. *Curr Eye Res* 2016;41: 1482–1488.
4. Ahmad M, Kaszubski PA, Cobbs L, et al. Choroidal thickness in patients with coronary artery disease. *PLoS One* 2017;12: e0175691.
5. Pumariega NM, Smith RT, Sohrab MA, et al. A prospective study of reticular macular disease. *Ophthalmology* 2011;118: 1619–1625.

6. Xu L, Blonska AM, Pumariega NM, et al. Reticular macular disease is associated with multilobular geographic atrophy in age-related macular degeneration. *Retina* 2013;33:1850–1862.
7. Klein R, Meuer SM, Knudtson MD, et al. The epidemiology of retinal reticular drusen. *Am J Ophthalmol* 2008;145:317–326.
8. Alten F, Clemens CR, Heiduschka P, Eter N. Localized reticular pseudodrusen and their topographic relation to choroidal watershed zones and changes in choroidal volumes. *Invest Ophthalmol Vis Sci* 2013;54:3250–3257.
9. Hayreh SS. In vivo choroidal circulation and its watershed zones. *Eye (Lond)* 1990;4:273–289.
10. Nesper PL, Soetikno BT, Fawzi AA. Choriocapillaris nonperfusion is associated with poor visual acuity in eyes with reticular pseudodrusen. *Am J Ophthalmol* 2017;174:42–55.
11. Smith RT, Sohrab MA, Busuioc M, Barile G. Reticular macular disease. *Am J Ophthalmol* 2009;148:733–743.
12. You QS, Camino A, Wang J, et al. Geographic atrophy progression is associated with choriocapillaris flow deficits measured with optical coherence tomographic angiography. *Invest Ophthalmol Vis Sci* 2021;62:28.
13. Alexander SL, Linde-Zwirble WT, Werther W, et al. Annual rates of arterial thromboembolic events in medicare neovascular age-related macular degeneration patients. *Ophthalmology* 2007;114:2174–2178.
14. Keilhauer CN, Fritsche LG, Guthoff R, et al. Age-related macular degeneration and coronary heart disease: evaluation of genetic and environmental associations. *Eur J Med Genet* 2013;56:72–79.
15. Wang J, Xue Y, Thapa S, et al. Relation between age-related macular degeneration and cardiovascular events and mortality: a systematic review and meta-analysis. *Biomed Res Int* 2016;2016:8212063.
16. Smith RT, Merriam JE, Sohrab MA, et al. Complement factor H 402H variant and reticular macular disease. *Arch Ophthalmol* 2011;129:1061–1066.
17. Curcio CA, Messinger JD, Sloan KR, et al. Subretinal drusenoid deposits in non-neovascular age-related macular degeneration: morphology, prevalence, topography, and biogenesis model. *Retina* 2013;33:265–276.
18. Sawa M, Ueno C, Gomi F, Nishida K. Incidence and characteristics of neovascularization in fellow eyes of Japanese patients with unilateral retinal angiomatous proliferation. *Retina* 2014;34:761–767.
19. Flamendorf J, Agron E, Wong WT, et al. Impairments in dark adaptation are associated with age-related macular degeneration severity and reticular pseudodrusen. *Ophthalmology* 2015;122:2053–2062.
20. Lee J, Choi S, Lee CS, et al. Neovascularization in fellow eye of unilateral neovascular age-related macular degeneration according to different drusen types. *Am J Ophthalmol* 2019;208:103–110.
21. Lee H, Kim S, Kim MA, et al. Integrative analysis of the choroid by quantifying Haller vessel and choriocapillaris parameters in different drusen subtypes. *Sci Rep* 2021;11:15509.
22. Domalpally A, Agron E, Pak JW, et al. Prevalence, risk, and genetic association of reticular pseudodrusen in age-related macular degeneration: age-related eye disease study 2 report 21. *Ophthalmology* 2019;126:1659–1666.
23. Lin LY, Zhou Q, Hagstrom S, et al. Association of single-nucleotide polymorphisms in age-related macular degeneration with pseudodrusen: secondary analysis of data from the comparison of AMD treatments Trials. *JAMA Ophthalmol* 2018;136:682–688.
24. Spaide RF. Improving the age-related macular degeneration construct: a new classification system. *Retina* 2018;38:891–899.
25. Yao H, Hou C, Liu W, et al. Associations of multiple serum biomarkers and the risk of cardiovascular disease in China. *BMC Cardiovasc Disord* 2020;20:426.
26. Lambert NG, ElShelmani H, Singh MK, et al. Risk factors and biomarkers of age-related macular degeneration. *Prog Retin Eye Res* 2016;54:64–102.
27. Williams BL, Seager NA, Gardiner JD, et al. Chromosome 10q26-driven age-related macular degeneration is associated with reduced levels of HTRA1 in human retinal pigment epithelium. *Proc Natl Acad Sci U S A* 2021;118:115.
28. Colijn JM, den Hollander AI, Demirkan A, et al. Increased high-density lipoprotein levels associated with age-related macular degeneration: evidence from the EYE-RISK and European eye epidemiology consortia. *Ophthalmology* 2019;126:393–406.
29. Monés J, Biarnés M. Geographic atrophy phenotype identification by cluster analysis. *Br J Ophthalmol* 2017;102:388–392.